

Ulnar Nerve Anatomy Diagram

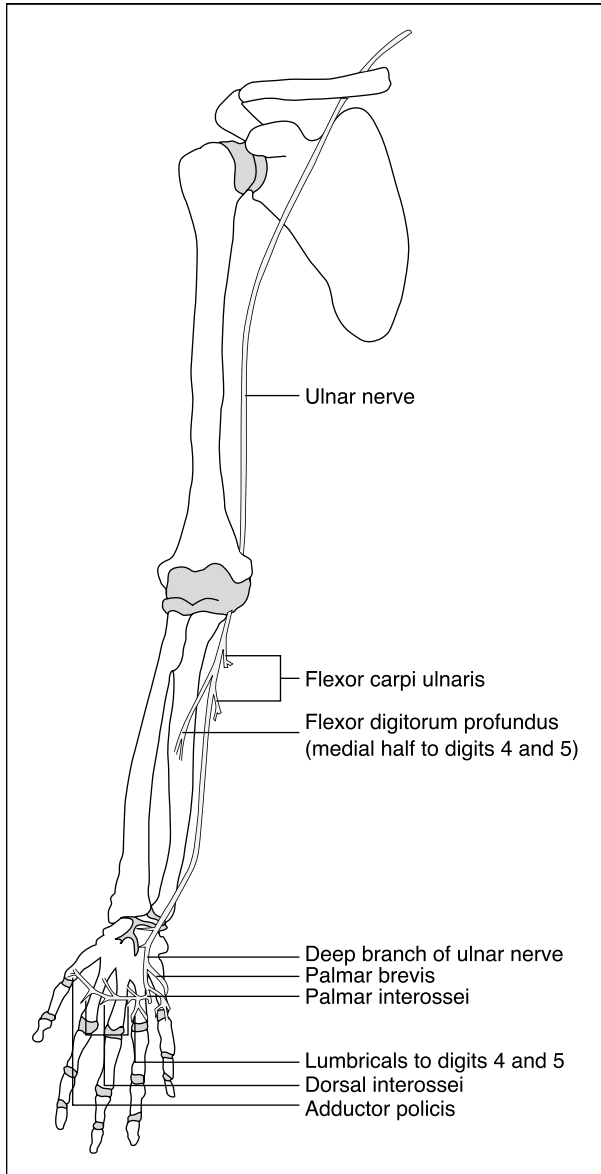
The ulnar nerve is major peripheral nerve in the upper limb, vital for various motor and sensory functions.

Spinal roots: C8-T1

Motor functions:

- **Forearm:** Controls the flexor carpi ulnaris and part of the flexor digitorum profundus.
- **Hand:** Influences most intrinsic hand muscles, excluding the thenar muscles and two lateral lumbricals.

Sensory functions: Provides sensation to the medial one and half fingers and the adjacent palm area.

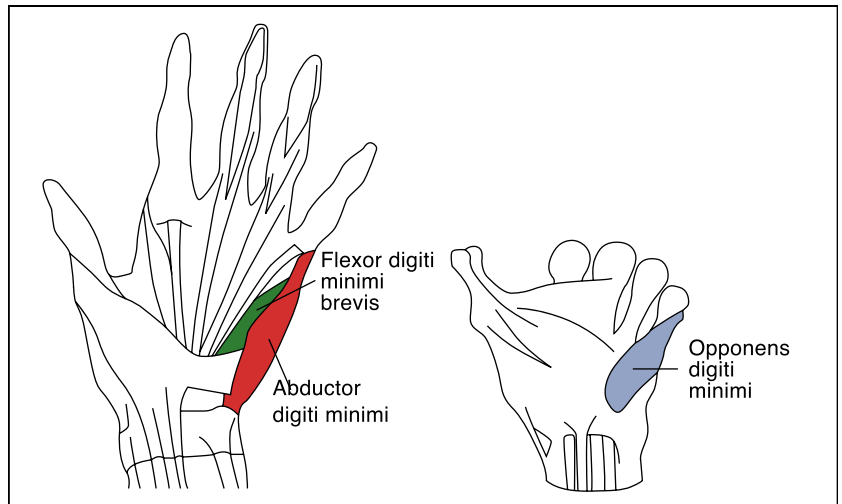


Anatomical pathway

The ulnar nerve originates from the brachial plexus in the axilla. It continues from the medial cord, containing fibers from C8 and T1 spinal roots. It descends through the medial arm, bypassing the axillary artery and vein. Midway down the arm, it moves into the posterior compartment and traverses the ulnar tunnel at the elbow. In the forearm, it passes between the heads of the flexor carpi ulnaris and travels beside the ulna. Three main branches emerge here:

- **Muscular branch:** Supplies two forearm muscles.
- **Palmar cutaneous branch:** Innervates the medial half of the palm.
- **Dorsal cutaneous branch:** Covers the dorsal medial one and a half fingers and associated hand area.

At the wrist, the nerve lies above the flexor retinaculum, beside the ulnar artery, and enters the hand through Guyon's canal, dividing into superficial and deep branches (deep branch of ulnar nerve).



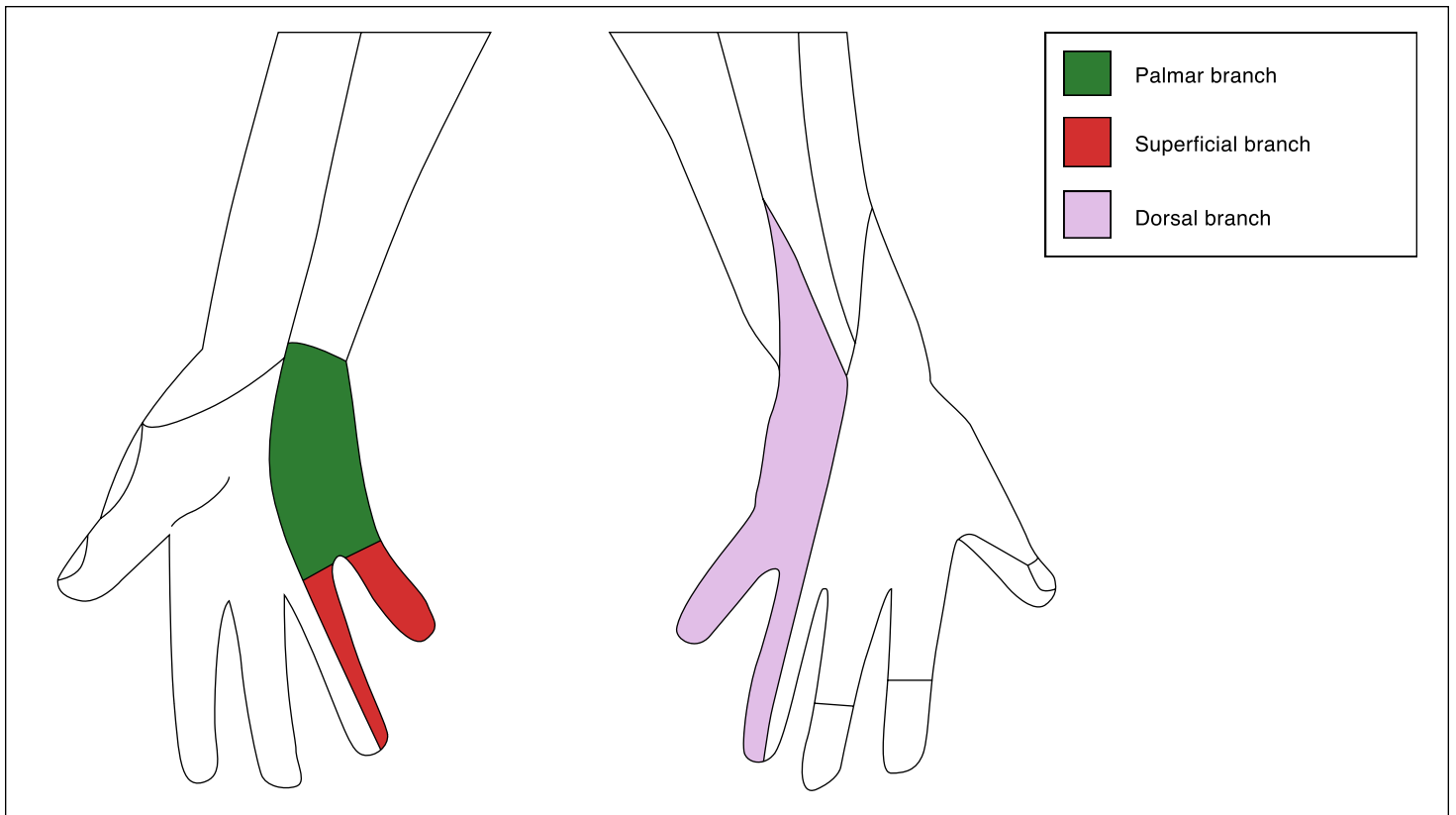
Motor functions

Forearm

- **Flexor carpi ulnaris:** Manages wrist flexion and adduction.
- **Flexor digitorum profundus (medial half to digits 4 and 5):** Flexes the distal joints of the ring and little fingers.

Hand

- **Hypothenar muscles:** Includes flexor digiti minimi brevis, abductor digiti minimi, and opponens digiti minimi.
- **Medial two lumbricals (to digits 4 and 5)**
- **Adductor pollicis**
- **Palmar interossei and dorsal interossei:** Aid in finger movement.
- **Palmaris brevis:** Controlled by the superficial ulnar branch.



Sensory functions

The ulnar nerve's sensory branches include:

- **Palmar cutaneous branch:** Innervates the medial palm.
- **Dorsal cutaneous branch:** Covers the dorsal medial one and a half fingers and adjacent hand area.
- **Superficial branch:** Affects the palmar side of the medial one and a half fingers.

Additional notes

Jones, O. (2019). *The ulnar nerve - course - motor - sensory*. TeachMeAnatomy. <https://teachmeanatomy.info/upper-limb/nerves/ulnar-nerve/>

Medbullets. (n.d.). *Ulnar nerve - MSK - Medbullets step 1*. <https://step1.medbullets.com/msk/121976/ulnar-nerve>