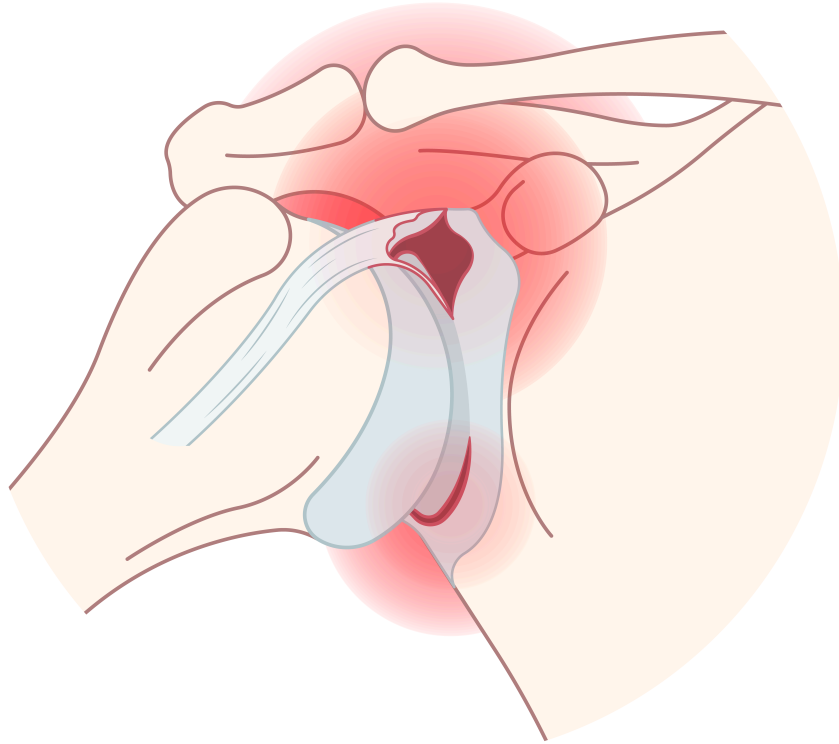


# SLAP Lesion Treatment Guidelines

---



Superior labrum anterior to posterior (SLAP) lesions, or SLAP tears, are injuries to the shoulder joint that affect the labrum and biceps tendon. The term SLAP stands for superior labrum anterior and posterior, indicating that the tear occurs at the top (superior) part of the shoulder socket, where the labrum meets the biceps tendon.

---

## Treatment options

Treating SLAP lesions typically begins with nonoperative approaches, but surgical intervention may be necessary depending on the severity of the injury and the patient's specific needs. Below are some of the common treatment methods.

### Nonoperative management

For most SLAP injuries, initial treatment involves nonoperative management. This approach includes the use of anti-inflammatory medications to reduce pain and swelling, cryotherapy (ice application) to manage inflammation, and modifications in activity to prevent further stress on the shoulder joint. Patients are often advised to rest and avoid activities that exacerbate their symptoms. These measures can be effective in managing SLAP tears, particularly in less severe cases.

## Surgical Treatment

When conservative management fails to yield results, surgical intervention becomes essential. The choice of surgical technique depends on the specific type of SLAP lesion:

- **Type I Lesions**

Characterized by labral fraying, these lesions are typically treated through debridement, which involves removing damaged tissue to create a stable edge.

- **Type II Lesions**

As the most common type, these lesions often necessitate arthroscopic repair. This procedure involves reattaching the labrum to the glenoid using sutures or suture anchors to restore stability.

- **Type III Lesions**

These lesions feature a bucket-handle tear of the labrum, which is usually excised, and the remaining labrum is smoothed to ensure stability.

- **Type IV Lesions**

Involving the biceps tendon, treatment options may include tenotomy (cutting the tendon) or tenodesis (reattaching the tendon at a different site), combined with labral repair, depending on the severity of tendon damage.

## Physical therapy management

Physical therapy management is essential for patients recovering from SLAP lesions. For individuals with Type I SLAP lesions, conservative treatment may be sufficient. This typically begins with a cessation of throwing activities and a short course of anti-inflammatory medication to reduce pain and inflammation. Once pain subsides, physical therapy focuses on restoring normal shoulder motion and strengthening the shoulder girdle musculature, which is critical for maintaining proper shoulder biomechanics.

## Postoperative rehabilitation

For patients undergoing SLAP repair, postoperative rehabilitation varies based on the type of SLAP lesion and the specific surgical procedure performed. Initially, the patient's shoulder is immobilized in internal rotation using a sling. The following is a general guideline for postoperative rehabilitation:

- **Week 0 to 3**

The shoulder remains immobilized, with external rotation and abduction limited to 60°. Patients can perform pendulum exercises and elbow range-of-motion exercises.

- **Week 4 to 8**

Sling use is discontinued, and shoulder motion is gradually increased using active-assisted and passive techniques. External rotation is limited to 30° to minimize strain on the labrum, while internal and external rotation activities progress to 90° of shoulder abduction.

- **Week 8**

Resistance exercises focusing on scapular strengthening can be initiated, provided the patient has achieved approximately 115° to 120° of shoulder external rotation. Resisted biceps activities are prohibited for two months to protect the healing of the biceps anchor.

- **Week 16**

A sport-directed throwing program can commence for overhead athletes, focusing on exercises such as forward flexion in a side-lying position, prone extension, seated rowing, and serratus punch (protraction with the elbow extended).

- **Week 24**

Patients can generally return to contact sports, depending on their progress and recovery.

---

## **Additional notes**

---

## **References**

OrthoInfo. (2010). *SLAP tears*. American Academy of Orthopaedic Surgeons. <https://orthoinfo.aaos.org/en/diseases--conditions/slap-tears/>

Physiopedia. (2014). *SLAP lesion*. [https://www.physio-pedia.com/SLAP\\_Lesion](https://www.physio-pedia.com/SLAP_Lesion)

Wilk, K. E., Macrina, L. C., Cain, E. L., Dugas, J. R., & Andrews, J. R. (2013). The recognition and treatment of superior labral (slap) lesions in the overhead athlete. *International Journal of Sports Physical Therapy*, 8(5), 579–600. <https://www.ncbi.nlm.nih.gov/pmc/articles/PMC3811737/>