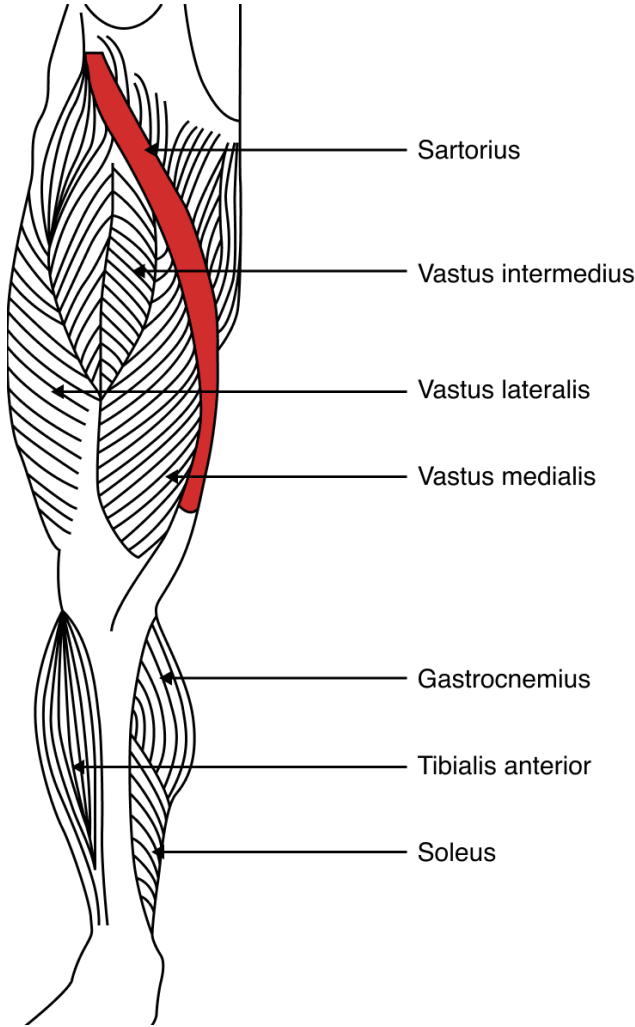


# Sartorius Anatomy Diagram

	<b>Origin</b>	Anterior superior iliac spine (ASIS)
	<b>Path</b>	Medial aspect of the tibia crossing the hip and inner knee joints
	<b>Insertion point</b>	Medial side of the proximal tibia
	<b>Role</b>	Facilitating the following essential movements: <ul style="list-style-type: none"> <li>• Hip and knee flexion</li> <li>• External rotation</li> <li>• Lateral rotation of the femur</li> </ul>
	<b>Fun fact</b>	The sartorius muscle is also known as the "tailor's muscle" because it helps with the cross-legged position which tailors adopted before.

## Additional notes