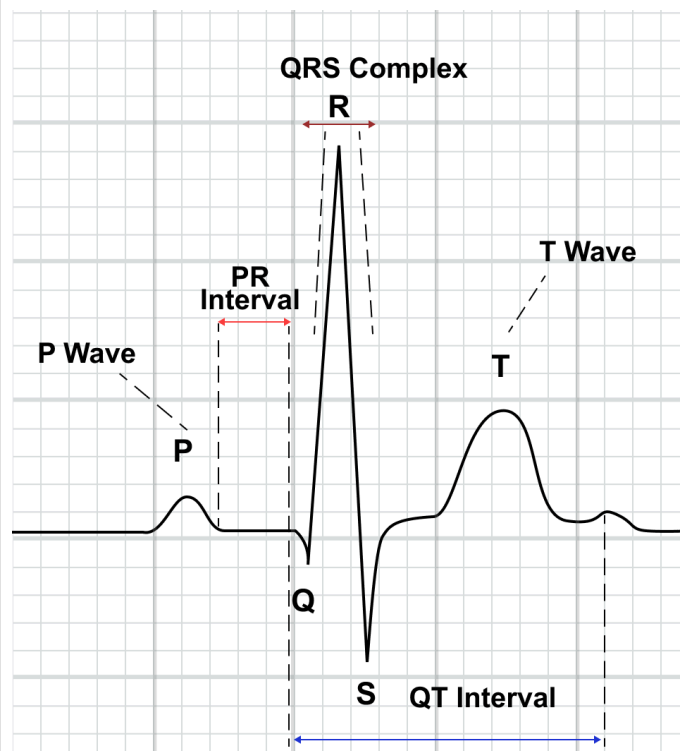


Normal ECG Values Chart

Name:		Sex:	
Age:	Date:		
Diagnosis:			
Medical history:			

ECG component	Normal range
Heart rate (HR)	60 - 100 beats per minute
P wave duration	0.06 - 0.12 seconds
PR interval	0.12 - 0.22 seconds
QRS complex duration	≤ 0.12 seconds
QT interval	0.36-0.44 seconds
QTc interval (corrected QT)	0.36-0.44 seconds or Males: ≤ 450 milliseconds Females: ≤ 470 milliseconds
T wave deflection	At least 5 of the 6 limb leads
T wave duration	0.1-0.25 seconds



Additional notes

References

ECG & ECHO Learning. (2017, May 30). *ECG interpretation: Characteristics of the normal ECG (P-wave, QRS complex, ST segment, T-wave)*. <https://ecgwaves.com/topic/ecg-normal-p-wave-qrs-complex-st-segment-t-wave-j-point/>

Rosenthal, L. (2024, February 16). *Normal Electrocardiography (ECG) Intervals: Normal Electrocardiography Intervals*. EMedicine. <https://emedicine.medscape.com/article/2172196-overview?form=fpf>

Sharma, R. (2024, March 26). *Normal ECG values chart explained*. Sunfox. <https://sunfox.in/blogs/normal-ecg-values-chart-explained/>