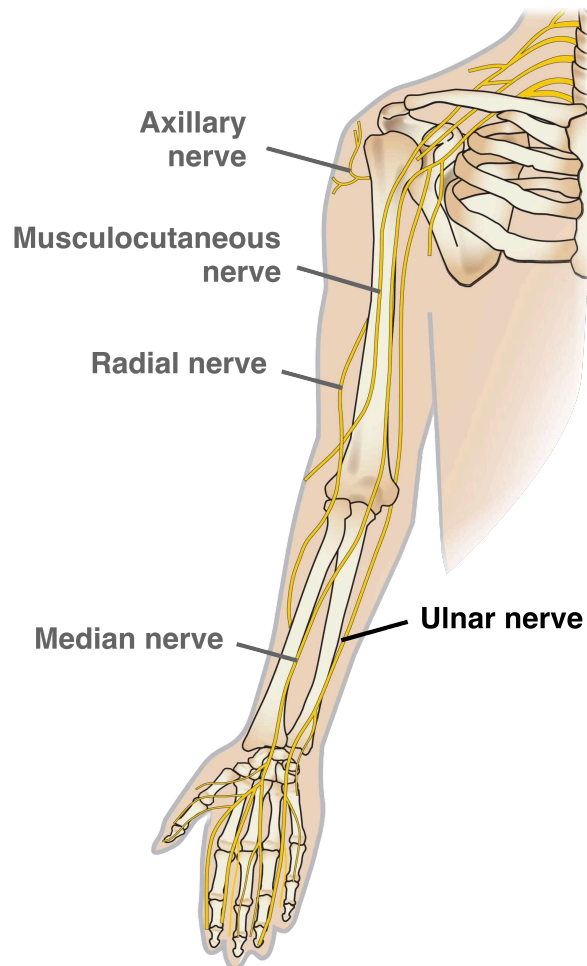


Median Nerve Anatomy



Key information	
Anatomical course	Path down the upper arm passing through the cubital fossa
Function	Innervating the flexor muscles used for gripping and pinching Supplying the thenar and lumbrical muscles for fine hand movements Providing sensation to specific hand areas
Conditions	Carpal tunnel syndrome Simian hand Hand of benediction
Additional notes	