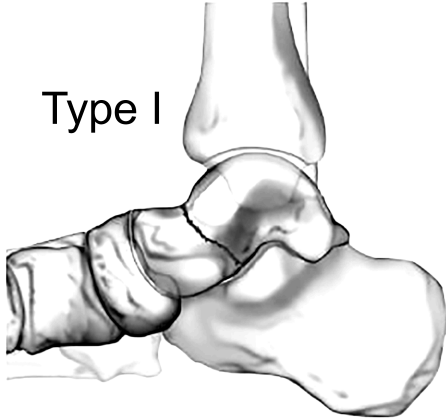


Hawkins Classification Chart

The Hawkins Classification Chart is a system used to categorize talar neck fractures. These are fractures in the thinnest cross-sectional portion of the talus, just proximal to the talar head.

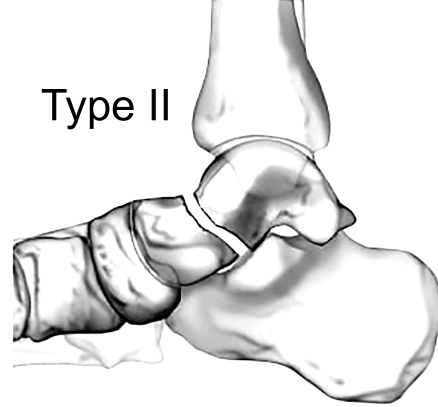
Type I



Type I:

The Hawkins type I refers to a nondisplaced talar neck fracture. This condition has a 0-13% avascular necrosis (AVN) risk rate.

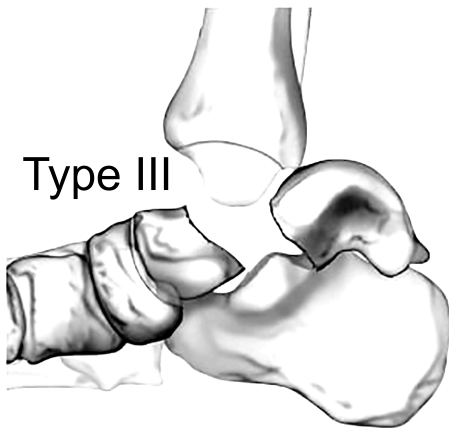
Type II



Type II:

A Hawkins type II injury is a talar neck fracture accompanied by subtalar dislocation, with an AVN risk rate of 20-50%.

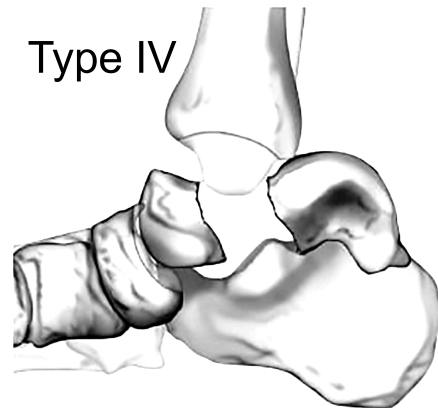
Type III



Type III:

A Hawkins type III fracture involves full displacement of the talar neck, along with dislocations of either the subtalar or ankle joint, carrying an an AVN risk between 20% and 100%.

Type IV



Type IV:

A Hawkins type IV injury refers to a talar neck fracture accompanied by subtalar, tibiotalar, and talonavicular dislocation. The associated risk of AVN ranges from 70-100%.

Cadogan, M. (2021, February 1). *Hawkins classification*. Life in the Fast Lane. <https://litfl.com/hawkins-classification/>

Weatherford, B. (2023, December 23). *Talar neck fractures - trauma - Orthobullets*. Orthobullets. <https://www.orthobullets.com/trauma/1048/talar-neck-fractures>