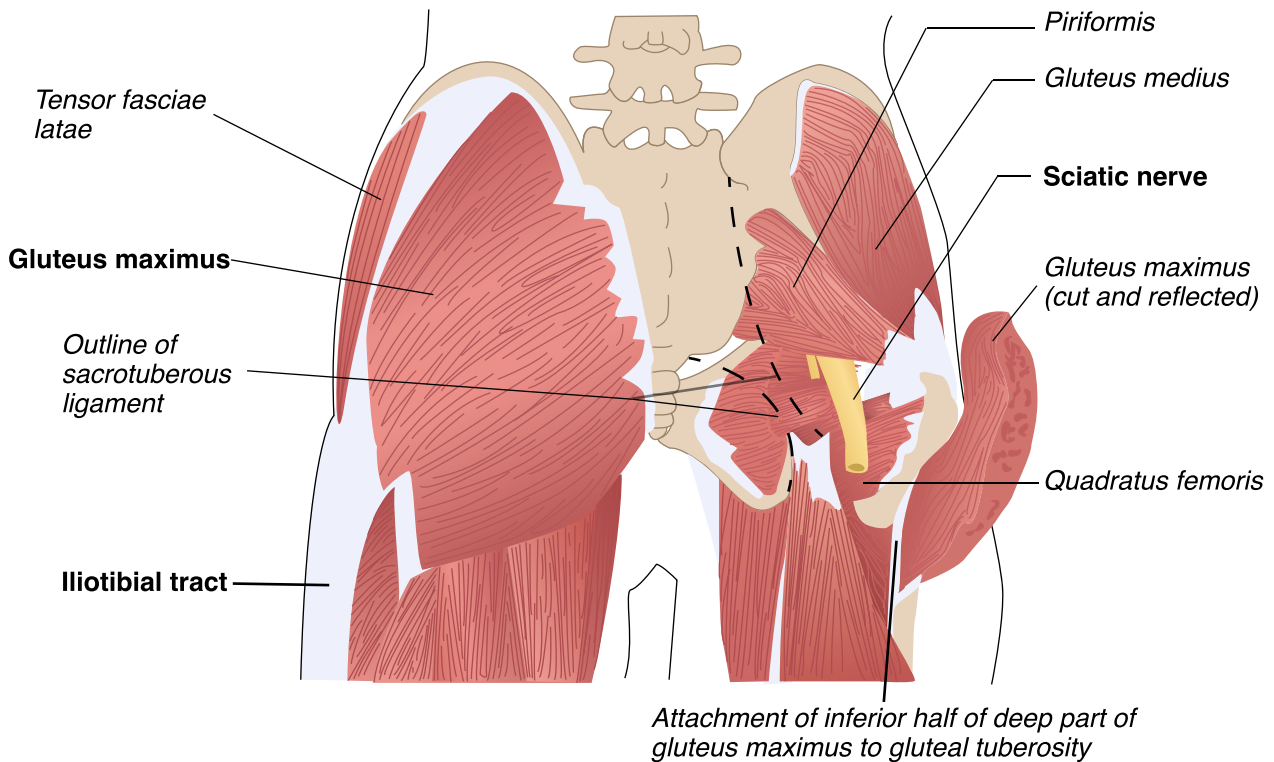


# Gluteus Medius Anatomy Diagram

## Posterior view



The diagram depicts the gluteal muscles and their anatomical relationships from a posterior view, highlighting the gluteus medius, gluteus maximus, and gluteus minimus. Key features include:

- **Gluteus medius:** Positioned laterally on the hip, crucial for hip abduction and pelvis stabilization.
- **Gluteus maximus:** The largest, most superficial muscle, responsible for hip extension and external rotation.
- **Gluteus minimus:** Located beneath the gluteus medius, aiding in thigh abduction and medial rotation.
- **Superior and inferior gemellus:** Small muscles aiding in lateral thigh rotation and hip stabilization.
- **Piriformis:** Lateral thigh rotator and hip stabilizer.
- **Obturator internus:** Lateral rotator and hip stabilizer.
- **Quadratus femoris:** Assists in lateral rotation and hip stabilization.
- **Thighbone (Femur):** Supports body weight and facilitates lower limb movement.
- **Sacrum:** Connects spine to pelvis, supporting upper body weight.

## Additional notes

Deleget, A. (2020, September 8). Gluteus medius: My favorite muscle. *Dance Medicine New Mexico*. <https://www.dancemedicinem.com/post/gluteus-medius-my-favorite-muscle>