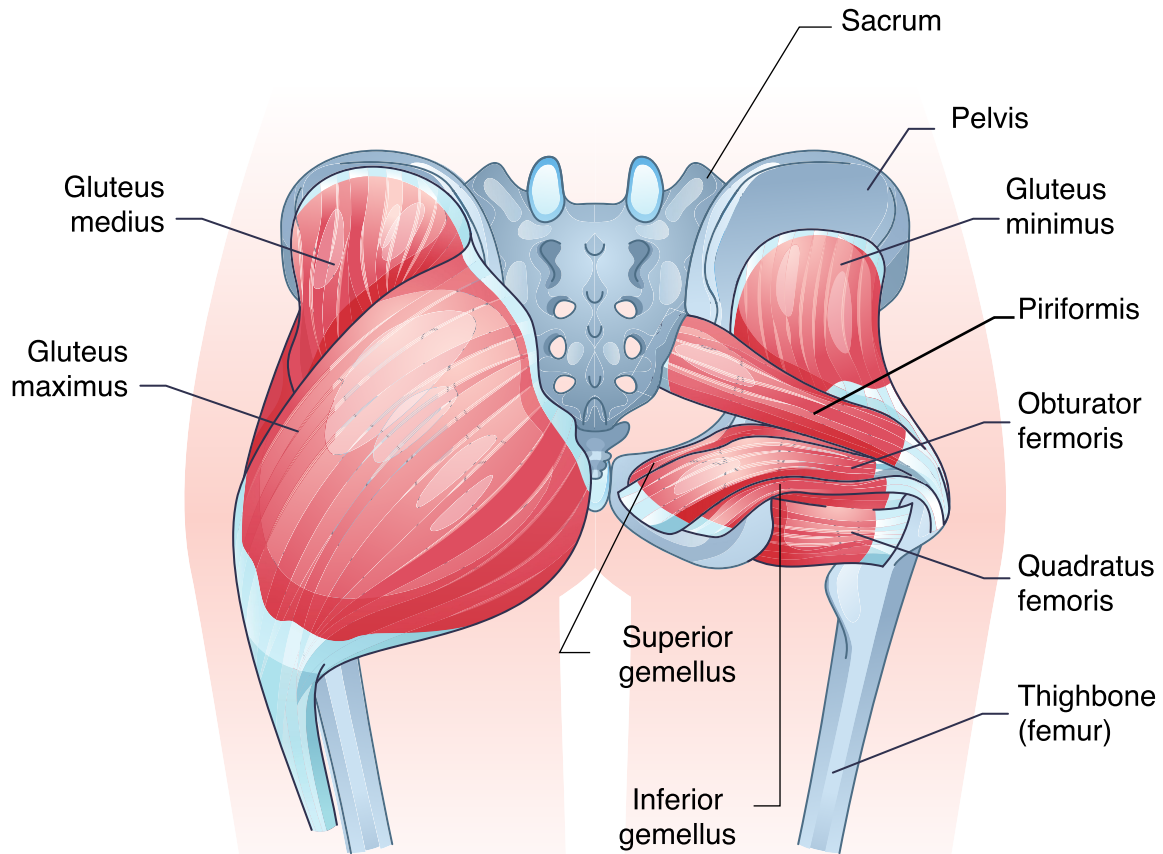


Glute Muscle Diagram



- **Gluteus medius:** The gluteus medius is located on the outer surface of the pelvis and is essential for hip abduction and stability. It helps keep the pelvis level during walking and is supplied by the superior gluteal nerve and superior gluteal arteries.
- **Gluteus maximus:** The gluteus maximus is the largest gluteal muscle responsible for extending and externally rotating the hip. It plays a key role in standing up, climbing stairs, and running. It attaches to the gluteal tuberosity and the iliotibial tract. It is innervated by the inferior gluteal nerve.
- **Gluteus minimus:** The gluteus minimus is located underneath the gluteus medius and assists with hip abduction and internal rotation. It stabilizes the pelvis during movement and is innervated by the superior gluteal nerve.
- **Pelvis:** The pelvis is the basin-shaped structure that supports the spine and contains the hip bones. It is the attachment site for gluteal muscles, including the gluteus maximus, medius, and minimus.
- **Sacrum:** The sacrum is a triangular bone at the base of the spine that connects the spine to the pelvis. It provides stability to the lower body and forms part of the back of the pelvis.
- **Piriformis muscle:** The piriformis is a small muscle that helps rotate the hip and stabilize the sacrum. It lies near the sciatic nerve, which can cause sciatica if the piriformis becomes tight or inflamed.
- **Obturator internus:** The obturator internus is a deep hip muscle involved in external rotation of the thigh. It stabilizes the hip joint and works with other external rotators.
- **Quadratus femoris:** The quadratus femoris is a square-shaped muscle located on the posterior side of the hip. It functions to externally rotate the femur and stabilize the hip joint.
- **Superior gemellus:** The superior gemellus is a small muscle that helps externally rotate the hip and stabilize the femur. It works closely with the obturator internus.

- **Inferior gemellus:** The inferior gemellus works similarly to the superior gemellus and helps with external rotation and hip stabilization.
- **Thighbone (Femur):** The femur is the longest and strongest bone in the body, connecting the hip to the knee. It provides attachment points for the gluteal muscles, including the gluteal tuberosity, where the gluteus maximus inserts.


Great glute exercises

- **Squats:** Target **all the glute muscles**, promoting strength and endurance.
- **Lunges:** Help develop the **gluteus maximus** and **medius** for better stability.
- **Hip thrusts:** Focus on the **gluteus maximus**, boosting muscle activation and power.

Common glute injuries and treatment

- **Piriformis syndrome:** Caused by irritation or compression of the sciatic nerve. Treatment includes stretching, massage, and strengthening exercises.
- **Gluteal strain:** Overuse or sudden movement injuries. Treatment involves rest, ice, and physical therapy.
- **Sciatica:** Caused by tight glute muscles pressing on the sciatic nerve. Treatment includes stretching and targeted strengthening.

Additional notes



America Hip Institute & Orthopedic Specialists. (n.d.). What are signs and symptoms of gluteus maximus injury? <https://www.americanhipinstitute.com/blog/what-are-signs-and-symptoms-of-gluteus-maximus-injury-31451.html>

Elzanie, A., Borger, J. (2023). Anatomy, bony pelvis and lower limb, gluteus maximus muscle. In: StatPearls [Internet]. Treasure Island (FL): StatPearls Publishing. <https://www.ncbi.nlm.nih.gov/books/NBK538193/>

Neto, W. K., Soares, E. G., Vieira, T. L., Aguiar, R., Chola, T. A., Sampaio, V. de L., & Gama, E. F. (2020). Gluteus maximus activation during common strength and hypertrophy exercises: A systematic review. *Journal of Sports Science & Medicine*, 19(1), 195–203. <https://www.ncbi.nlm.nih.gov/pmc/articles/PMC7039033/>